

Inferior Epigastric Artery a Boon in Accessory Lower Polar Artery Revascularization in Renal Transplantation

Kabilan Saminathan^{1,*}, Balaraman Velayutham², Muthu Veeramani³

¹Department of Urology, Dr Mehta's Hospital, Chennai, India

²Department of Nephrology, Institute of Child Health, Dr MGR Medical University, Chennai, India

³Department of Urology, SRM Institute of Medical Sciences, Chennai, India

Email address:

kabildr@yahoo.co.in (Kabilan Saminathan)

*Corresponding author

To cite this article:

Kabilan Saminathan, Balaraman Velayutham., Muthu Veeramani. Inferior Epigastric Artery a Boon in Accessory Lower Polar Artery Revascularization in Renal Transplantation. *International Journal of Clinical Urology*. Vol. 7, No. 1, 2023, pp. 1-4.

doi: 10.11648/j.ijcu.20230701.11

Received: December 11, 2022; **Accepted:** January 3, 2023; **Published:** January 13, 2023

Abstract: Multiple renal arteries occur unilaterally and bilaterally in 23% and 10% of the population, respectively. During renal transplantation failure to recognize and preserve an accessory renal artery may lead to ureteral necrosis, segmental renal infarction, postoperative hypertension, or calyceal fistula formation. The problem with accessory renal artery is prolonged ischemia and delayed graft function. Long ischemia can be avoided if lower polar accessory renal artery is anastomosed to inferior epigastric artery after de-clamping as soon as the main renal artery and venous anastomosis is done. Aim: In this study we report our experience with live donor renal transplantation with multiple arteries in which the lower polar artery was anastomosed to the inferior epigastric artery. This study describes the surgical technique and outcomes of live donor renal allografts with multiple arteries in which the lower polar artery was anastomosed to the inferior epigastric artery after de-clamping. Material & Methods: Between 2012 and 2020, 68 consecutive live donor renal transplants were performed involving single Urology-Nephrology team. This included 48 with single and 20 with multiple arteries. Anastomosis of the lower polar artery to the inferior epigastric artery was used for 8 grafts with multiple arteries. Results: Successful revascularization of all areas of the transplanted graft was confirmed by Doppler ultrasonography in most patients and radionuclide renal scanning + MRA in some patients. Conclusions: In live donor renal transplantation with multiple arteries; the anastomosis of the lower polar artery to the inferior epigastric artery after de-clamping, avoids prolongation of the ischemia time that occur with other surgical techniques.

Keywords: Multiple Renal Artery Transplantation, Inferior Epigastric Artery, Renal Transplantation

1. Introduction

Multiple renal arteries were a relative contraindication for donation. Because of the shortage in donor pool, grafts with multiple arteries are needed to be accepted. Good techniques have resulted in good outcomes in grafts with multiple vessels. [1-5] In cadaveric donors Pollack et al noted that the incidence of multiple arteries in 28% of cases and multiple veins in 8 % of cases. [6] Multiple renal arteries occur unilaterally in 23% and bilaterally in 10% of the population. Lower polar accessory arteries are more important than upper polar because of ureteric vascularity. In living donor selection, it a

better to have a small upper pole artery, so that it can be safely tied. But a lower pole artery of 2-3 mm caliber must be selected for safe microvascular anastomosis. Failure to revascularize the lower polar vessels can lead to ureteric necrosis and urine leak. Five different ways of lower polar arterial revascularization are described: 1. Vein patch, 2. Direct anastomosis to the external iliac artery, 3. common anastomosis of polar artery and renal artery, 4. Polar artery to Main renal artery, 5. Anastomosis with inferior epigastric artery. [7, 8] Although other techniques for lower polar accessory artery revascularisation are described, the advantages of inferior epigastric artery are:

- 1) *Shorter ischemia time*, achieved by de-clamping as soon as the main renal artery and venous anastomosis is done.
- 2) *Long length* of Inferior epigastric artery helps to reach more medially placed lower pole arteries.

2. Method

2.1. Aim

Aim of the study is to assess the outcomes of live donor renal allografts with multiple arteries in which the lower polar artery was anastomosed to the inferior epigastric artery.

2.2. Study

2.2.1. Study Methodology

The study is a Retrospective type. Between Jan 2012 to Jan 2020 the live donor renal transplants done by a single Urology-Nephrology unit with multiple arteries were identified. Of these the recipients with lower pole accessory artery anastomosed to inferior epigastric artery were selected for the study. Doppler ultrasound is done to assess the flow in the lower pole. Good and uniform doppler flow is taken as successful outcome. Patients were followed for at least one year in the study. As per our unit protocol doppler study is done in all transplant recipients at the following points 1. At the time of discharge, 2. If post-operative graft function is not optimal, 3. Third month after transplant, 4. Sixth month of transplant, 5. A year after transplant, 6. when serum creatinine is rising or worsening, 7. Recent worsening of hypertension present. When there is excessive persistent drain output or perirenal collection the drain, the drain fluid or the aspirated fluid from the collection is sent for serum creatinine estimation. If they are elevated and correspond to the urine creatinine levels a urine leak is suspected and DTPA scan is done. Magnetic resonance Angiography done when doppler findings are suggestive of transplant renal artery stenosis.

2.2.2. Technique of Vascular Anastomosis

During recipient bed preparation as a protocol of our unit Inferior epigastric artery is preserved in all cases even if CT angiogram shows single artery. The inferior epigastric artery is disconnected at the level of the rectus muscle. Because in many live donor renal transplants the CT angiogram reports a single renal artery, but a lower polar vessel may be missed during the reporting. Usually the inferior epigastric artery and vein are tied together. The inferior epigastric artery and the vein are then wrapped in papaverine soaked gauze to allow for dilatation. The inferior epigastric vein is later separated from artery during anastomosis. Laparoscopic donor surgery is done in all left sided donors and R side laparoscopic surgery done if the renal vein length is more than 1.5 cm. If the renal vein length is less than 1.5 cm then open donor nephrectomy is carried out. Two 10 mm weck clips used for main renal artery and vein, two 5 mm weck clips used for accessory arteries. At the time of bench preparation two perfusion vascular cannula are kept ready. Usually a cold ringer lactate solution is used

for perfusion. The main renal artery is perfused first and then the accessory artery. The kidney is placed in a kidney tray filled with ice slush and covered with a gauze. Then the graft renal arteries and vein are carefully dissected to prevent injury, Figure 1. Care is taken not to hold the vessels directly, the crush injury caused by holding the vessel can lead to artery stenosis. The vessels are held by holding the periarterial adventitia. The main renal artery is anastomosed usually to the internal iliac artery end to end by using 6°0 proline sutures. If the internal iliac artery is diseased then the main renal artery anastomosed to the external iliac artery. Once the main renal artery and venous anastomosis are done the artery and venous clamps are released and haemostasis checked. Then the lower polar artery anastomosis is carried out. If the lower pole artery is of equal calibre to the main renal artery and close to the main renal artery a pantaloan anastomosis is carried out. If lower polar vessel is large calibre and away from the main renal artery then a separate anastomosis is done to the external iliac artery. Small lower polar artery which is size matched to the inferior epigastric artery are anastomosed together. If the inferior epigastric artery is not satisfactory then a separate anastomosis to the iliac artery is done. Joining the lower polar artery to the main renal artery is not preferred in our unit. In an instance a short lower polar artery was lengthened by using the donor gonadal vein and anastomosed to the external iliac artery. Lower pole artery anastomosis done by applying a soft bulldog clamp to the inferior epigastric artery. Anastomosis to lower polar vessel started, figure 2. Two 7°0 proline with two needles are used and a magnifying loop at least 2.5X is required. Ends of both the arteries are spatulated at 6°0 in one and 12°0 clock in the other. Inner layer is by continuous suture from 12 to 6°0 clock. Outer layer done starting from 12 and 6°0 clock and completing at 9°0 clock. At the end of anastomosis the bull dog clamp is released and the lower pole of kidney turning pink is noticed. There must also be brisk bleeding from the cut end of the ureter with peristalsis if revascularisation is successful.

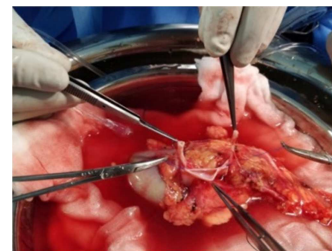
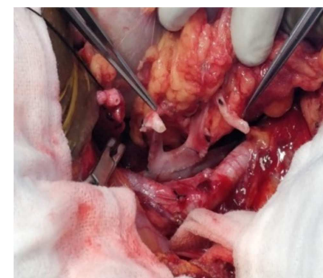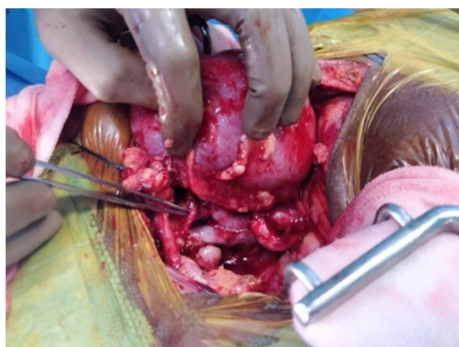


Figure 1. Bench dissection of Arteries and Vein.



(a) vein anastomosis completed



(b) Main renal artery to internal iliac artery and lower pole artery to inferior epigastric artery

Figure 2. Vascular anastomosis.

3. Results

Between Jan 2012 and Jan 2020, 68 consecutive live donor renal transplants were performed involving single Urology-Nephrology team. In this 48 transplants were with single renal artery and 20 were with multiple renal arteries. Anastomosis of the lower polar artery to the inferior epigastric artery was done in 8 grafts. Successful revascularization in all 8 transplanted grafts was confirmed by Doppler ultrasonography which was done in all patients. DTPA radionuclide renal scanning done in two patients to rule out urine leak corroborated the doppler findings. MRI Renal Angiography was done in one patient where renal artery stenosis was suspected and found to be normal with good lower pole anastomosis. [table 1].

Table 1. Results.

S. NO	Donor age	Recipient age	Relationship	Doppler: flow good	Magnetic Resonance Angiography (with indication)	DTPA scan (with indication)
1.	60	29	Father to son	yes	-	-
2.	39	45	Wife to husband	yes	-	Yes (Increased drain at 6 weeks)
3.	45	20	Sister to brother	yes	-	-
4.	61	30	Mother to son	yes	-	-
5.	65	40	Mother to daughter	yes	-	Yes (Pelvic collection)
6.	42	32	Sister to brother	yes	-	-
7.	42	47	Wife to husband	yes	YES (hypertension)	-
8.	62	35	Mother to daughter	yes	-	-

4. Discussion

Lower polar artery revascularization is very important because of ureteric blood supply. [7] The use of the inferior epigastric artery as a source of arterial inflow to the kidney was first described by Dubernard et al. in 1976. [9] Inferior epigastric artery is well suited for lower polar vessels that are shorter than 2 to 3 cm and smaller, 2 to 3 mm. [10] The inferior epigastric artery provides a good size matched and long conduit for small lower polar vessels. The procedure should not be taken lightly, it requires excellence in microvascular surgical principle. [11-13] A soft silicone splint may help in the anastomosis. [14] Some authors have used gonadal vein for lengthening the shorter lower polar artery before anastomosing to the external iliac artery. [15] But these require reconstruction and longer ischemia times. Longer ischemia times translate to Delayed graft function. EAU guidelines on renal transplantation states that there is twofold risk of graft failure over 5 years in grafts with Delayed Graft Function. As in our study other studies have reported good outcomes with inferior epigastric artery. [16-18] Studies have compared the outcomes of inferior epigastric artery with other techniques and found that the results are same. [16-18] Also the advantage of using inferior epigastric artery was in decreased re-warming ischemia than other techniques. [18] Though some surgeons prefer anastomosing small short lower pole arteries to the main renal artery, it is suggested by some authors not to follow this technique. As it is suggested that it is

best to avoid manipulating the main renal artery. [17] Also another reason to avoid joining the lower polar artery to the main renal artery is that Yamanaga et al reported poor outcomes when polar artery was anastomosed to the renal artery. [9].

The strength of the study is in that single surgeon and nephrologist were assessed. This gives a better assessment of individual team performance. Possible limitation will be the numbers because single team only were included in the study. Further studies are contemplated involving other teams and Cadaveric donors also. Also further studies to compare the other techniques used in revascularizing lower pole renal arteries are planned.

5. Conclusion

In live donor renal transplantation involving lower pole accessory using the inferior epigastric artery to revascularize is an ideal choice when they are of small calibre and short. It gives good outcomes with shorter ischemia time. Though they should not be taken lightly as it requires expertise in microvascular anastomosis technique.

References

- [1] Rossi M, Alfani D, Berloco P, Bruzzone P, Caricato M, Casciaro G, Poli L, Iappelli M, Pecorella I, Pretagostini R, et al. Bench surgery for multiple renal arteries in kidney transplantation from living donor. *Transplant Proc.* 1991 Oct; 23 (5): 2328-9. PMID: 1926377.

- [2] Pourmand G, Mehraban D, Ameli PJ, Ayati M, Naderi G. Donor polar kidney arteries: experience with 10 cases among 140 living-related kidney transplants. *Transplant Proc.* 1992 Oct; 24 (5): 1867. PMID: 1412888.
- [3] Guerra EE, Didoné EC, Zanotelli ML, Vitola SP, Cantisani GP, Goldani JC, Keitel E, Garcia VD. Renal transplants with multiple arteries. *Transplant Proc.* 1992 Oct; 24 (5): 1868. PMID: 1412889.
- [4] Belorussov OS, Goriañov VA, Milanov NO. Peresadka pochki s mnozhestvennymi arteriiami ot zhivogo rodstvennogo donora [Transplantation of the kidney with numerous arteries from a living relative-donor]. *Khirurgiia (Mosk).* 1991 Jan; (1): 106-9.
- [5] Brannen GE, Bush WH, Correa RJ Jr, Gibbons RP, Cumes DM. Microvascular management of multiple renal arteries in transplantation. *J Urol.* 1982 Jul; 128 (1): 112-5. doi: 10.1016/s0022-5347(17)52778-0. PMID: 7050410.
- [6] Pollak R, Prusak BF, Mozes MF. Anatomic abnormalities of cadaver kidneys procured for purposes of transplantation. *Am Surg.* 1986 May; 52 (5): 233-5. PMID: 3518559.
- [7] Young JS, Rohr MS. Use of the inferior epigastric artery to revascularize a lower pole renal artery in renal transplant. *Am Surg.* 1995 Feb; 61 (2): 185-6. PMID: 7856984.
- [8] Wolters HH, Schult M, Heidenreich S, Chariat M, Senninger N, Dietl KH. The anastomosis between renal polar arteries and arteria epigastrica inferior in kidney transplantation: an option to decrease the risk of ureter necrosis? *Transpl Int.* 2001 Dec; 14 (6): 442-4. doi: 10.1007/s001470100011. PMID: 11793043.
- [9] Yamanaga S, Rosario A, Fernandez D, Kobayashi T, Tavakol M, Stock PG, et al. (2018) Inferior long-term graft survival after end-to-side reconstruction for two renal arteries in living donor renal transplantation. *PLoS ONE* 13 (7): e0199629. <https://doi.org/10.1371/journal.pone.0199629>
- [10] Dubernard JM, Pin J, Gignoux N, Perrin J. Utilisation de l'artère épigastrique en transplantation rénale [Use of the epigastric artery in renal transplantation (author's transl)]. *J Urol Nephrol (Paris).* 1976 Jun; 82 (6): 469-72. French. PMID: 787554.
- [11] Gomes LJ, Goldstein MJ, Hardy MA. The use of inferior epigastric artery in renal transplantation. *Transplantation.* 2009 Sep 15; 88 (5): 748-9. doi: 10.1097/TP.0b013e3181b3923f. PMID: 19741476.
- [12] Novick AC. Microvascular reconstruction of complex branch renal artery disease. *Urol Clin North Am.* 1984 Aug; 11 (3): 465-75. PMID: 6380079.
- [13] Aguiló J, Rodríguez O, Gaete J, Galleguillos I. Vascular anastomosis techniques in renal transplants. *Int Angiol.* 1991 Jan-Mar; 10 (1): 39-43. PMID: 2071973. Russian.
- [14] P. Ostrowski, M. J. Kotowski, K. Tejchman, M. Szemitzko, J. Sieńko, M. Ostrowski, The Arterial Anastomosis Between Deep Inferior Epigastric Artery and Small Polar Renal Artery in Kidney Transplantation: A Case Report, *Transplantation Proceedings*, Volume 54, Issue 4, 2022, Pages 1145-1147.
- [15] Veeramani Muthu, Jain Vikas, Ganpule Arvind, Sabnis R B, Desai Mahesh R. Donor gonadal vein reconstruction for extension of the transected renal vessels in living renal transplantation. *Indian Journal of Urology*, 2010, Volume: 26, Issue 2, Pages: 314-316.
- [16] El-Sherbiny M, Abou-Elela A, Morsy A, Salah M, Foda A. The use of the inferior epigastric artery for accessory lower polar artery revascularization in live donor renal transplantation. *Int Urol Nephrol.* 2008; 40 (2): 283-7. doi: 10.1007/s11255-007-9257-z. PMID: 17721826.
- [17] Ioannis M. Antonopoulos, Kleiton Gabriel Ribeiro Yamaçake, Lorena M. Oliveira, Affonso C. Piovesan, Hideki Kanashiro, Willian C. Nahas, Revascularization of Living-Donor Kidney Transplant with Multiple Arteries: Long-term Outcomes Using the Inferior Epigastric Artery, *Urology*, Volume 84, Issue 4, 2014, Pages 955-959.
- [18] Kumar, A., Gupta, R. S., Srivastava, A. and Bansal, P. (2001), Sequential anastomosis of accessory renal artery to inferior epigastric artery in the management of multiple arteries in live related renal transplantation: a critical appraisal. *Clin Transplantation*, 15: 131-135.